Preprosthetic Surgery

Karl Cuddy BSc, DDS, MD, MSc, FRCD(C)

Assistant Professor
Director of Education and Maxillofacial Trauma
Graduate Program in Oral and Maxillofacial Surgery
Surgeon – Mt. Sinai Hospital

UNIVERSITY OF TORONTO
FACULTY OF DENTISTRY
ORAL AND MAXILLOFACIAL SURGERY

Lecture Goals

- Understand goals of preprosthetic surgery
- Understand breadth and limitations of preprosthetic sx
- Recognize who can benefit from preprosthetic sx
- Understand basic surgical techniques

Preprosthetic Surgery and Implants

- Preprosthetic Sx: Very common prior to implant therapy
- Implants
  - Improve denture retention
  - In select situations, if planned properly can obviate need for preprosthetic sx
  - Increase frequency of these surgeries but do not eliminate the need for these techniques
  - Implants + Preprosthetic surgery often only way to retain prosthesis after head and neck cancer reconstruction

Preprosthetic Evaluation

- History
  - Chief complaint & Patient Goals
  - Medical
  - Social
  - Family Hx
- Physical Exam/Clinical Exam
  - IPPA
- Radiographic exam
  - Plain Films
  - Orthopantomogram
  - Cephalogram
  - +/- CBCT/CT
- +/- study models

Preprosthetic Evaluation

- Clinical Exam
  - Maxillomandibular relationship
  - Bony projections/Undercuts
  - Tori
  - Ridge anomalies
  - Evaluation of insertion and origin of frenula
  - Muscle attachment
  - Quality and quantity of mucosa and gingiva

Preprosthetic Evaluation

- Radiographic Exam
  - Bony pathology
  - Impacted teeth
  - Retained roots
  - Sinus pneumatization
  - Neurovascular position

Preprosthetic Planning

Preprosthetic Surgery Goals

- Insertion
- Comfort
- Retention
- Stability
- Adequate occlusion
- Satisfactory appearance
- Avoid damage to oral tissues

Lawson WA. Objectives of pre-prosthetic surgery. Br J Oral Surg. 1972;10: 175-88

Insertion

- Adequate interarch space
- Clear path to place prosthesis
  - Free of:
    - Bony protruberances
    - Undercuts
    - Bulbous soft tissue protruberances
- Surgery to affect Insertion:
  - Alveoplasty
  - Tuberosity reduction
  - Tori and exostosis excision

Comfort

- Prosthesis must be seated in a stable position on good quality soft tissue overlying smooth bone
- Surgery to affect Comfort:
  - Alveoplasty
  - Excision of redundant soft tissue
  - Frenectomy
  - Vestibuloplasty +/- soft tissue grafting

Retention

- Prosthesis must resist vertical displacement
- Surface area contact maximized and sealed peripherally

- Surgery to affect Retention:
  - Frenectomy
  - Vestibuloplasty
  - Lowering of floor of mouth

Stability

- Prosthesis must resist lateral displacement
- Requires ridge height and appropriate quality and quantity of mucosa/gingiva
  - *Implants significantly affect stability

- Surgery to affect Stability:
  - Vestibuloplasty
  - Lowering of floor of mouth
  - Historically procedures to increase height of bony ridge
  - Bone Grafting

Adequate Occlusion

- Ideally class I maxillomandibular relationship

- Surgery to affect Stability:
  - LeFort I osteotomy
  - Bilateral Sagittal Split Osteotomy/Mandibular Osteotomies

Satisfactory Appearance

- Prosthodontic "finishing" of denture
- Requires appropriate selection of teeth +/- acrylic etc

- Surgery to affect Appearance:
  - LeFort I osteotomy
  - Bilateral Sagittal Split Osteotomy/Mandibular Osteotomies

Minimize Damage to Oral Tissue

- Evan, distributed transmission of forces from prosthesis to mucosa/gingiva/bone
- Appropriate tissue type to tolerate force

- Surgery to affect Minimize Long Term Tissue Damage:
  - Alveoplasty/Removal of undercuts
  - Vestibuloplasty
  - Soft Tissue Grafting

Alveoplasty

- Goals
  - Remove alveolar irregularities at time of extraction
  - Recontour alveolar ridge after bony and soft tissue healing have occurred
  - Preserve as much bone as possible
    - Facilitates future implant
    - Improves stability and retention of prosthesis
  - Allows appropriate tissue support and comfort for patient with prosthesis

Alveoplasty

- Techniques
  - Full thickness mucoperiosteal flap
  - Bur, rongeur, bone file, digital compression to alter bone
  - Remove loose bony spicules
  - Closure with plain gut/chromic gut

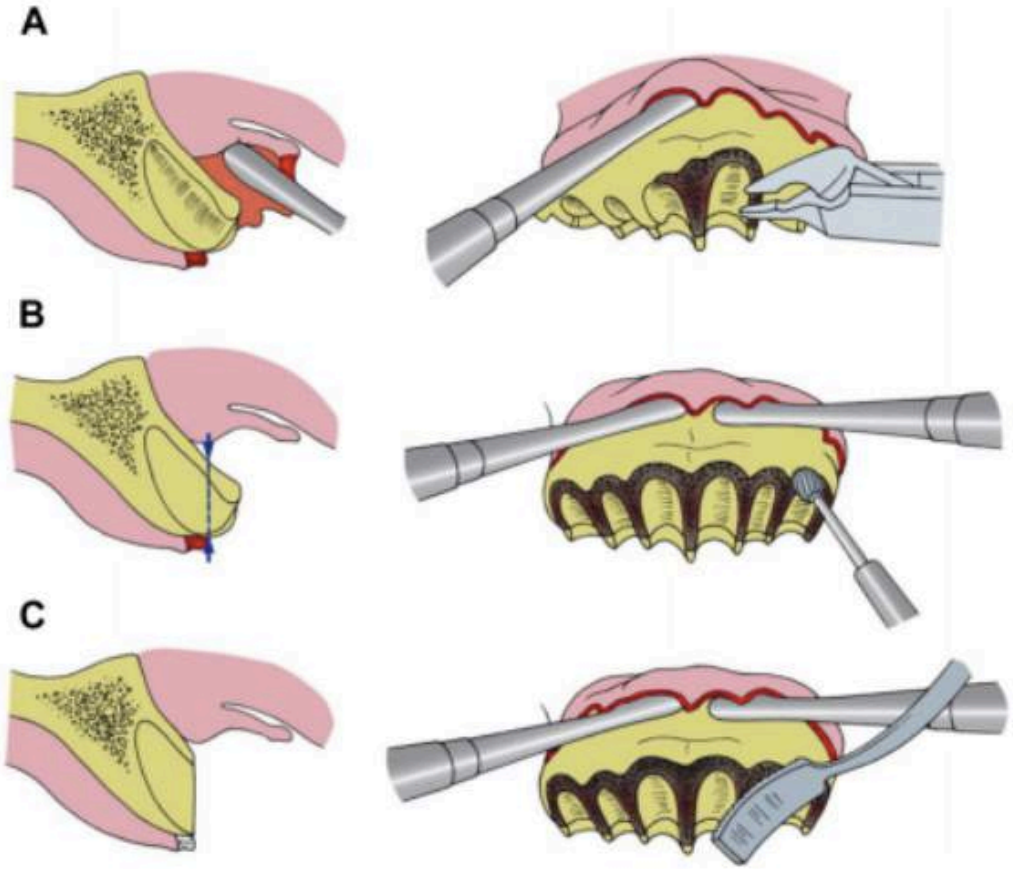

Alveoplasty

- Techniques
  - Full thickness mucoperiosteal flap
  - Bur, rongeur, bone file, digital compression to alter bone
  - Remove loose bony spicules
  - Closure with plain gut/chromic gut

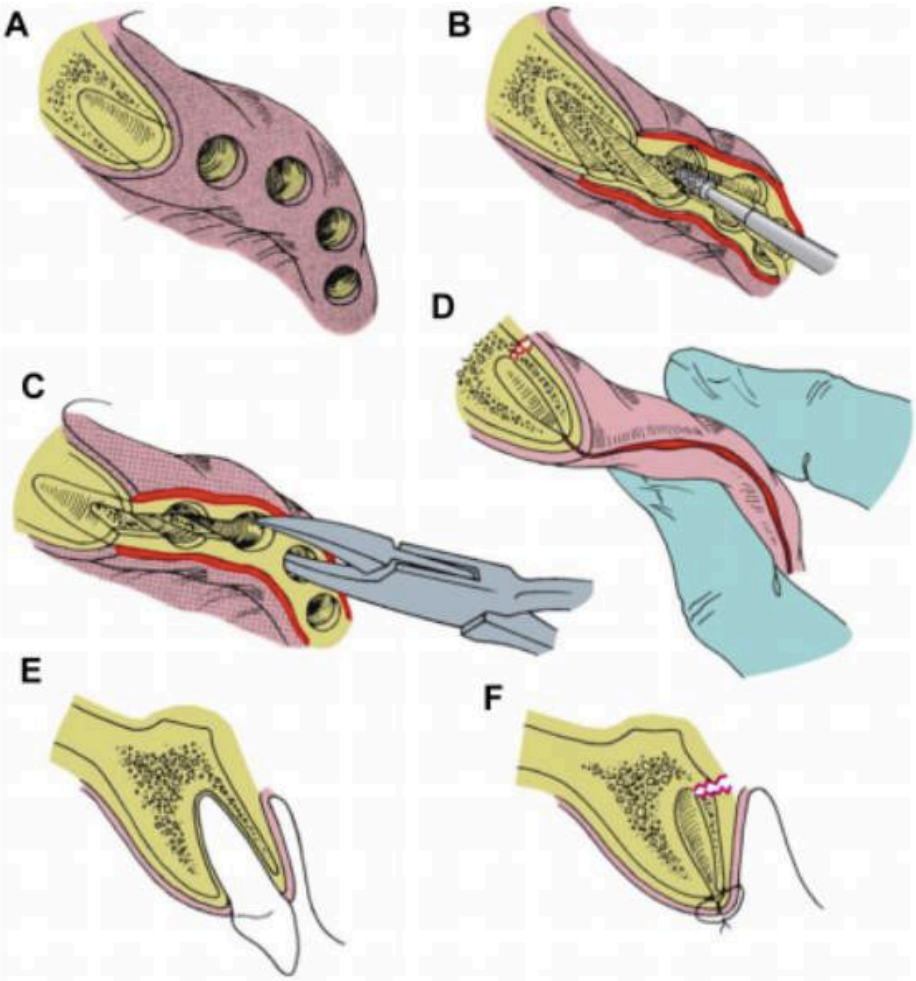

Maxillary Tuberosity Reduction

- Goals
  - Provide adequate inter-arch space for prosthesis fabrication (>1 cm)
  - Recontour and/or remove excess bone
  - Recontour and/or remove redundant soft tissue
  - Improve insertion, retention and stability

Maxillary Tuberosity Reduction

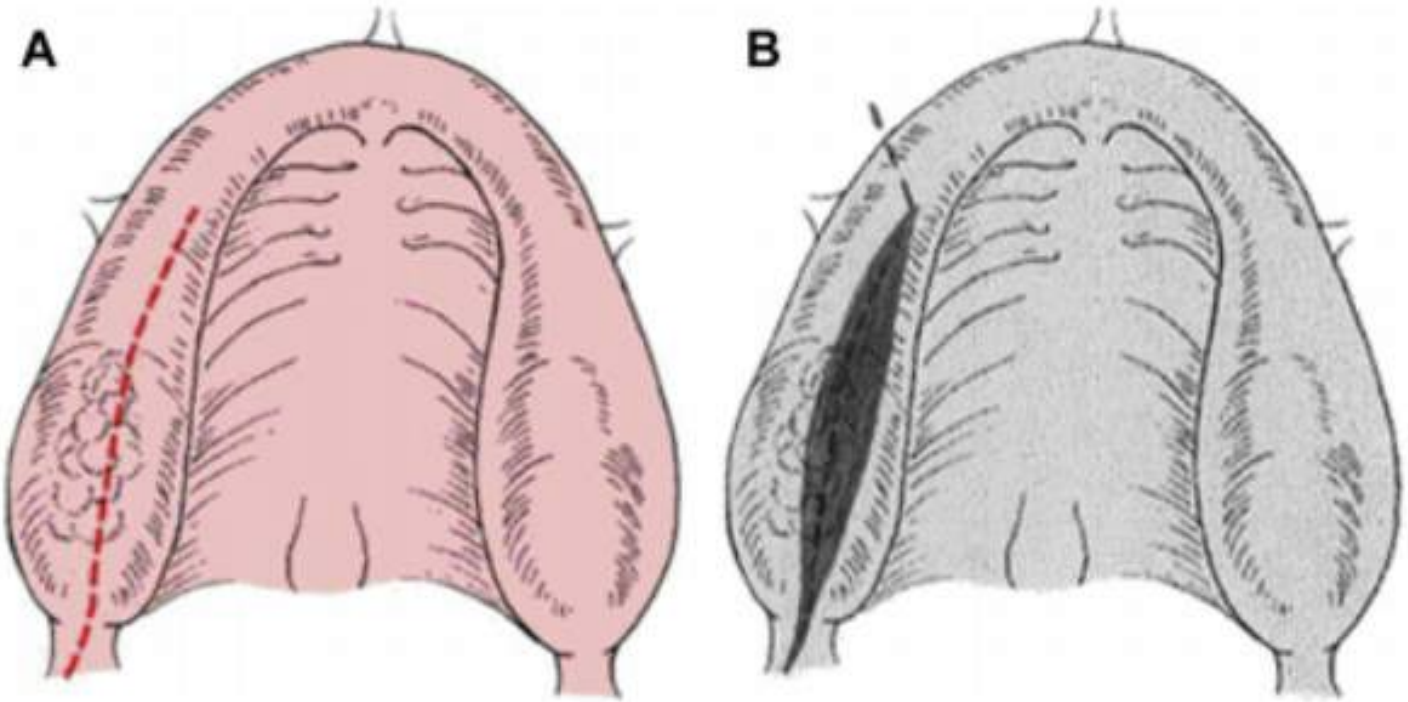

- Technique
  - Full thickness mucoperiosteal flap
  - Rongeur, bone file, bur to remove/recontour bone
  - Excise redundant mucosa, bevel incisions

Maxillary Tuberosity Reduction

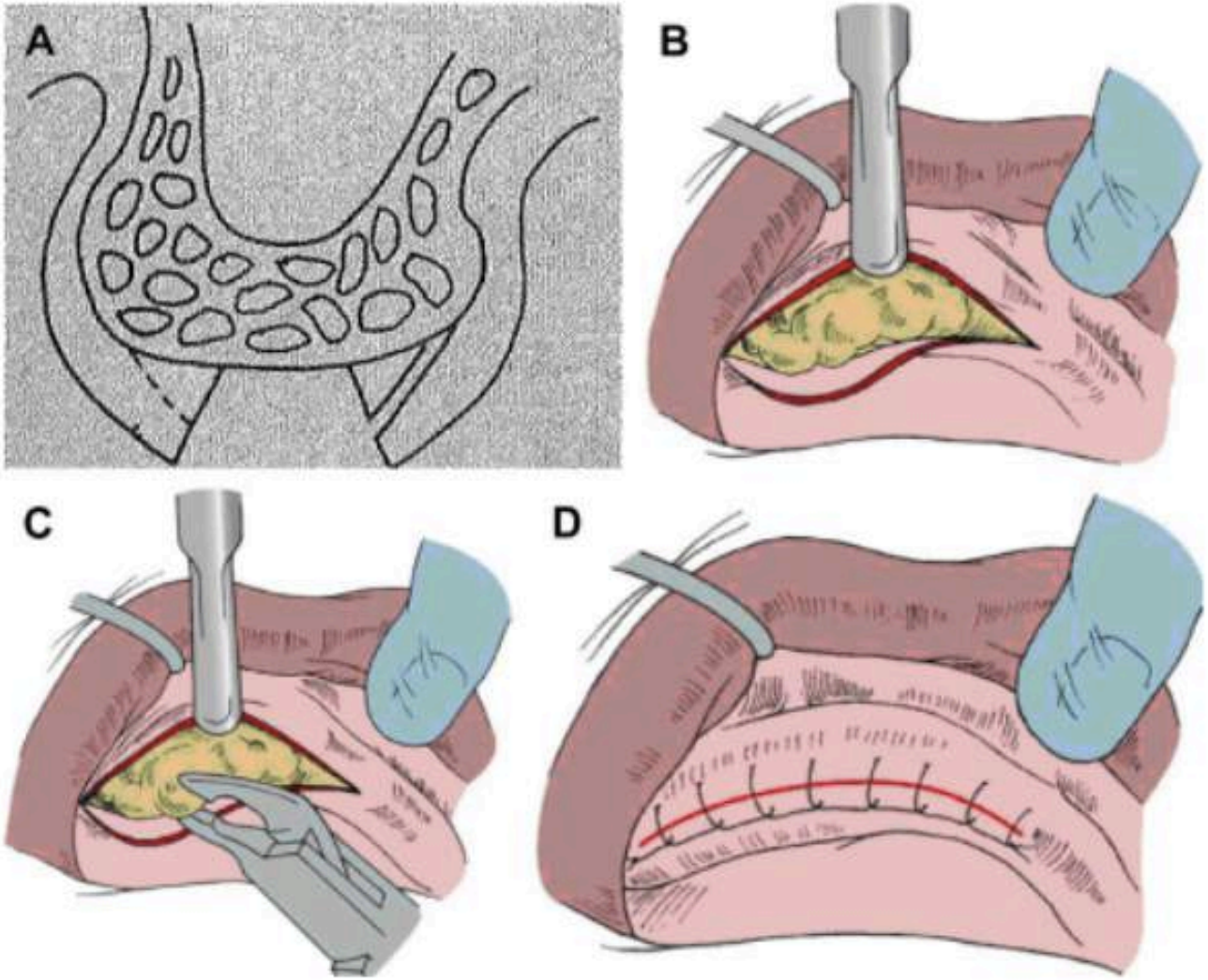

Maxillary Tuberosity Reduction

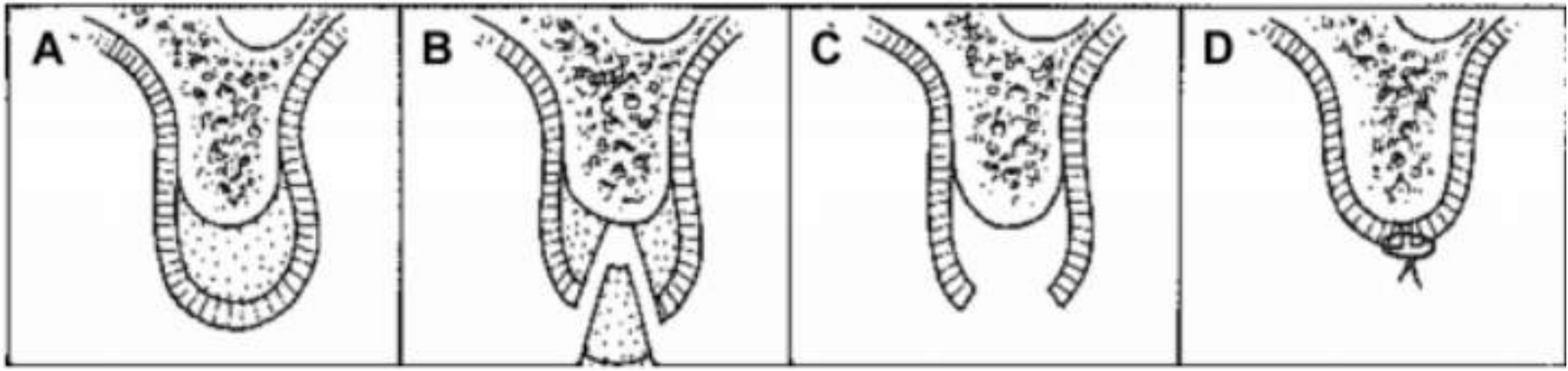

Management of Tori

- Dentate patients
  - Infrequently need to excise tori
    - Excise if recurrent, frequent ulcerations of thin mucosa overlying tori
- Edentulous/Partially Edentulous
  - Interfere with insertion
  - Effect comfort

Maxillary/Palatal Tori

- Pre-Operative Planning
  - Establish goals for removal/recontouring
  - Consider study model, with fabrication of splint/stent to provide pressure after excision
  - Discuss specific risks of oro-antral communication, need further surgery, dehiscence

Maxillary/Palatal Tori

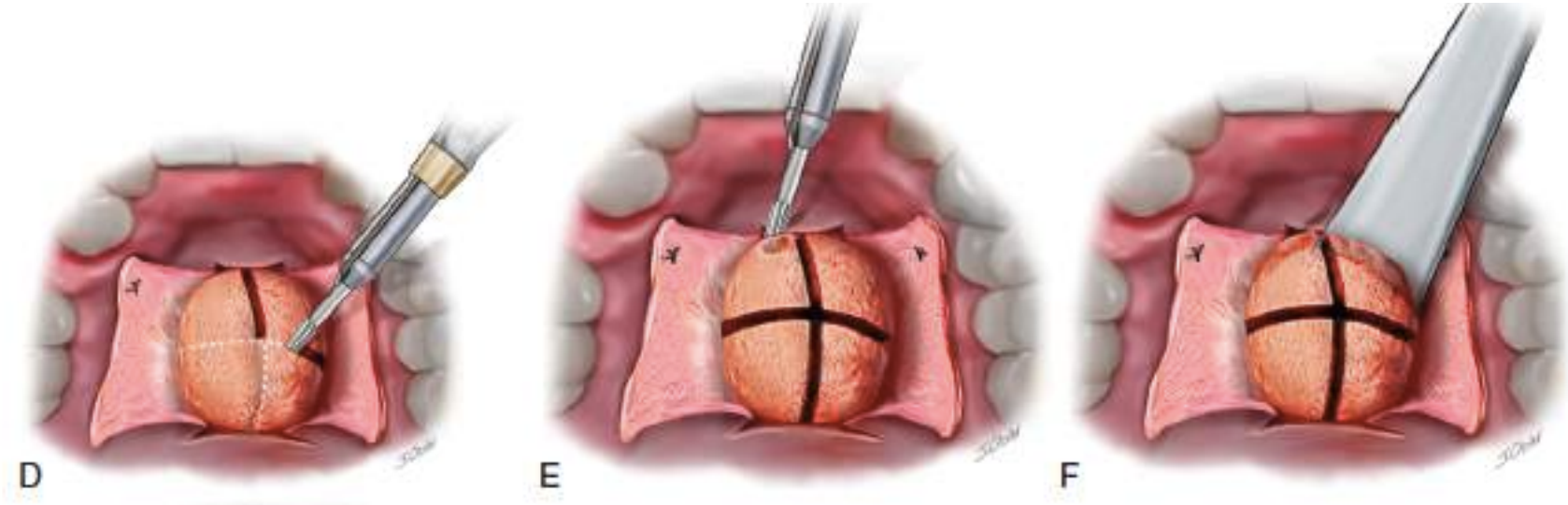

- Technique
  - Y or H shaped incisions
  - Technically challenging flap elevation – avoid perforations
  - Osteotomy + chisel, bur, rongeur for removal
  - Excise redundant tissue
  - Wound closure

Mandibular Tori

- Pre-Operative Planning
  - Understand prosthetic goals
  - Discuss risks of nerve injury
- Technical Considerations
  - Careful elevation of full thickness mucoperiosteal flap – easy to perforate
  - Retraction to protect contents of floor of mouth

Mandibular Tori

- Pre-Operative Planning
  - Understand prosthetic goals
  - Discuss risks of nerve injury
- Technical Considerations
  - Careful elevation of full thickness mucoperiosteal flap – easy to perforate
  - Retraction to protect contents of floor of mouth

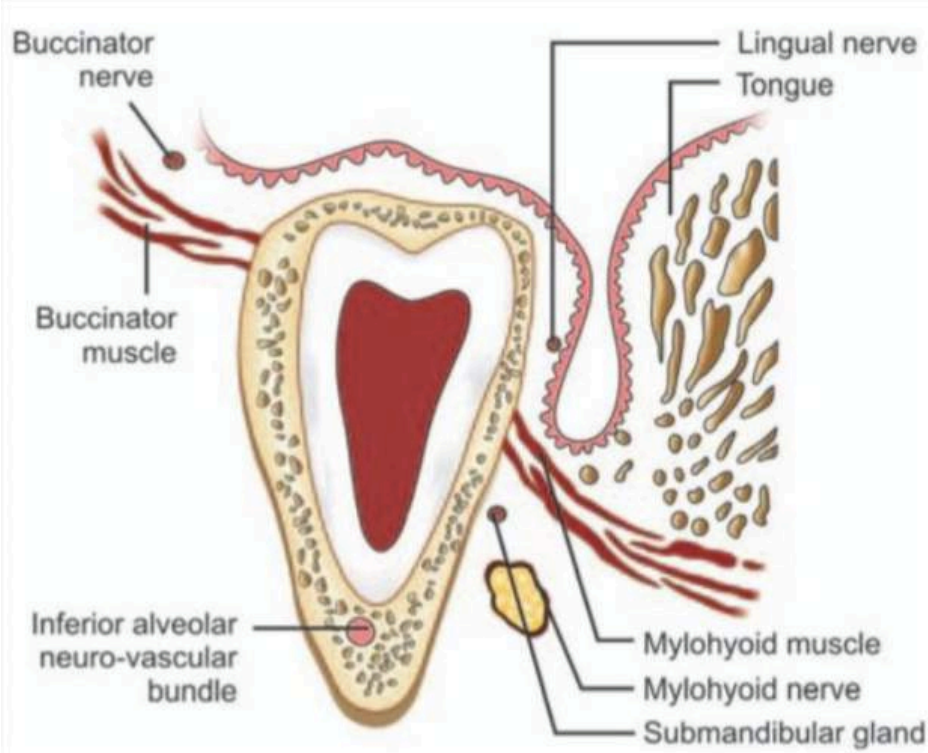

Mandibular Tori

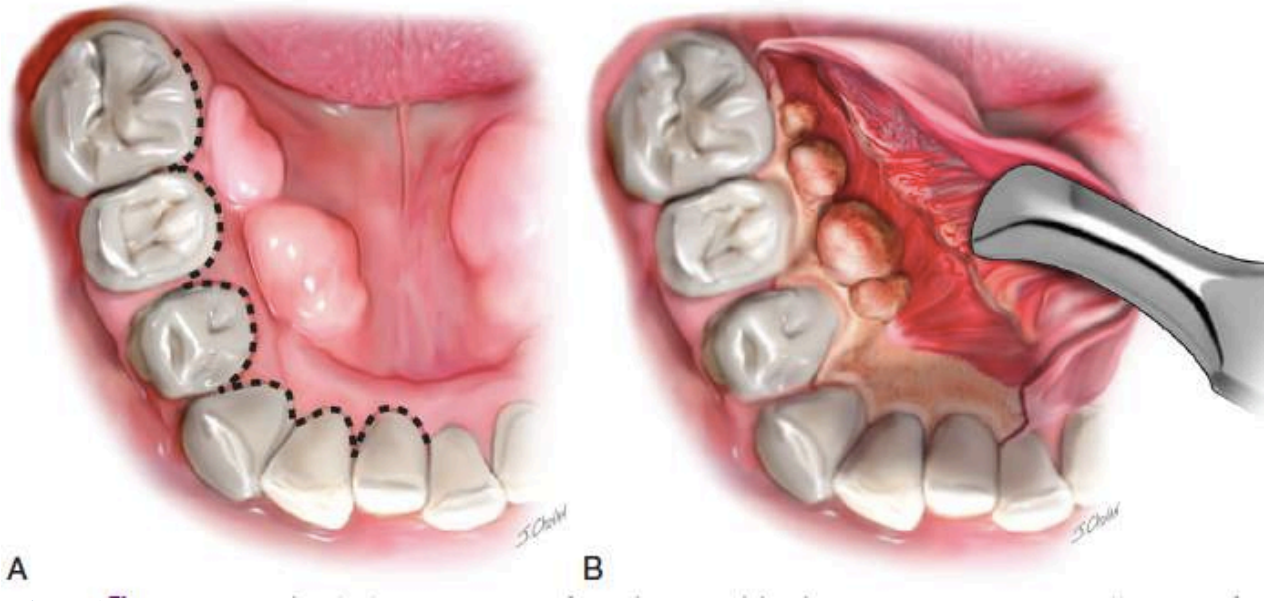

- Technique
  - Technically challenging flap elevation – avoid perforations
  - Bur, osteotomy, chisel, bone file to remove/recontour
  - Retractors to protect FOM
  - Consider pressure post-op to minimize risk of hematoma

Frenectomy

- Goal
  - Improve retention and stability
  - Remove and reposition mucosal and fibrous attachment
- Technique
  - Multiple techniques described
  - Simple excision, Z Plasty, Limited vestibuloplasty
  - Must excise fibrous attachment to bone

Frenectomy

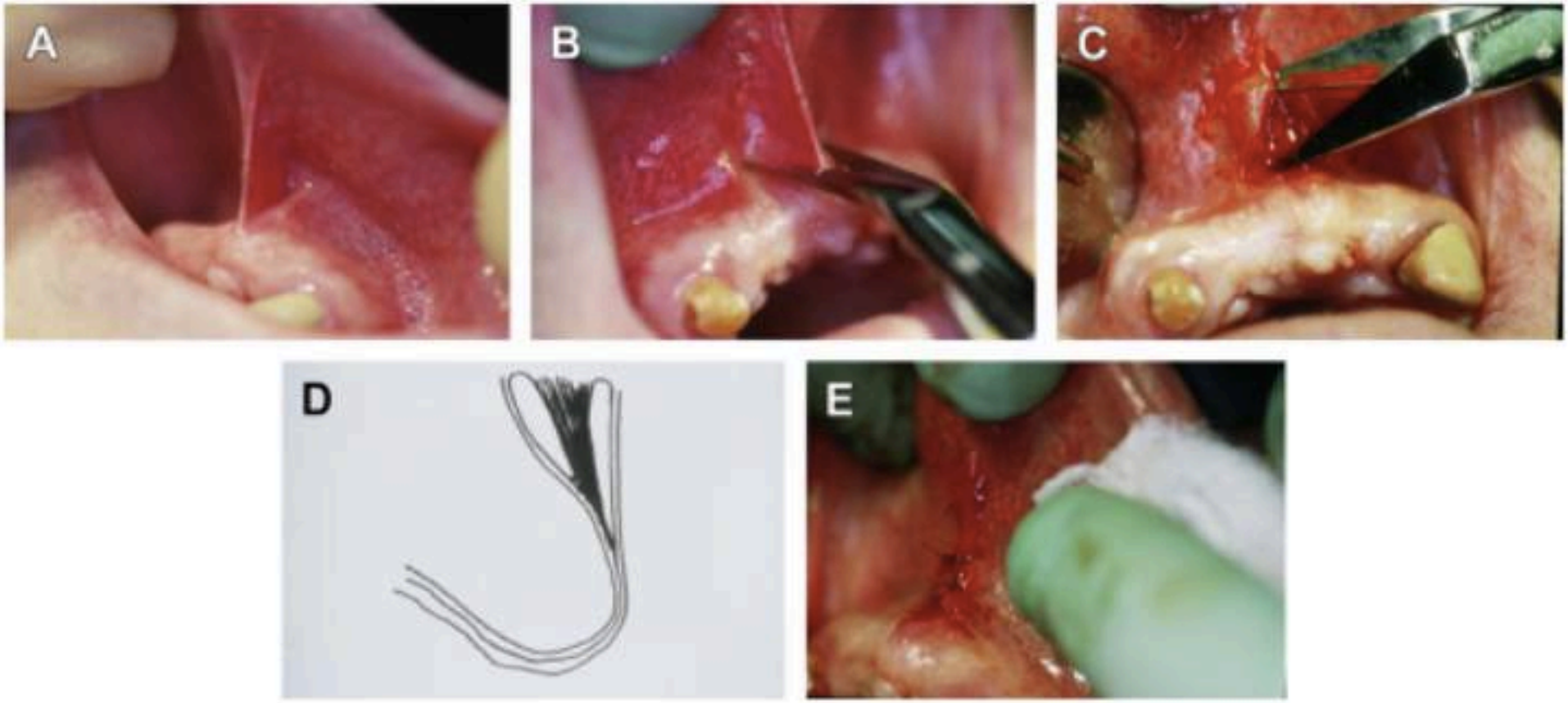

Vestibuloplasty

- Goal
  - Improve comfort, retention, stability, minimize damage to soft tissue
  - Increase depth of maxillary or mandibular vestibule
    - Allow patients with moderate alveolar atrophy to wear CUD/ CLD
  - Alter quality of soft tissue (i.e. keratinized as opposed to non-keratinized)
    - Allow edentulous patient with unfavourable soft tissue attachments to have a comfortable, stable tissue bed
    - Allow patients with implants to have improved mucosal health around implants, and to have comfort in implant retained, tissue born prosthesis

Clark/Kazanjian Vestibuloplasty

- Lip incision area heals by secondary intention

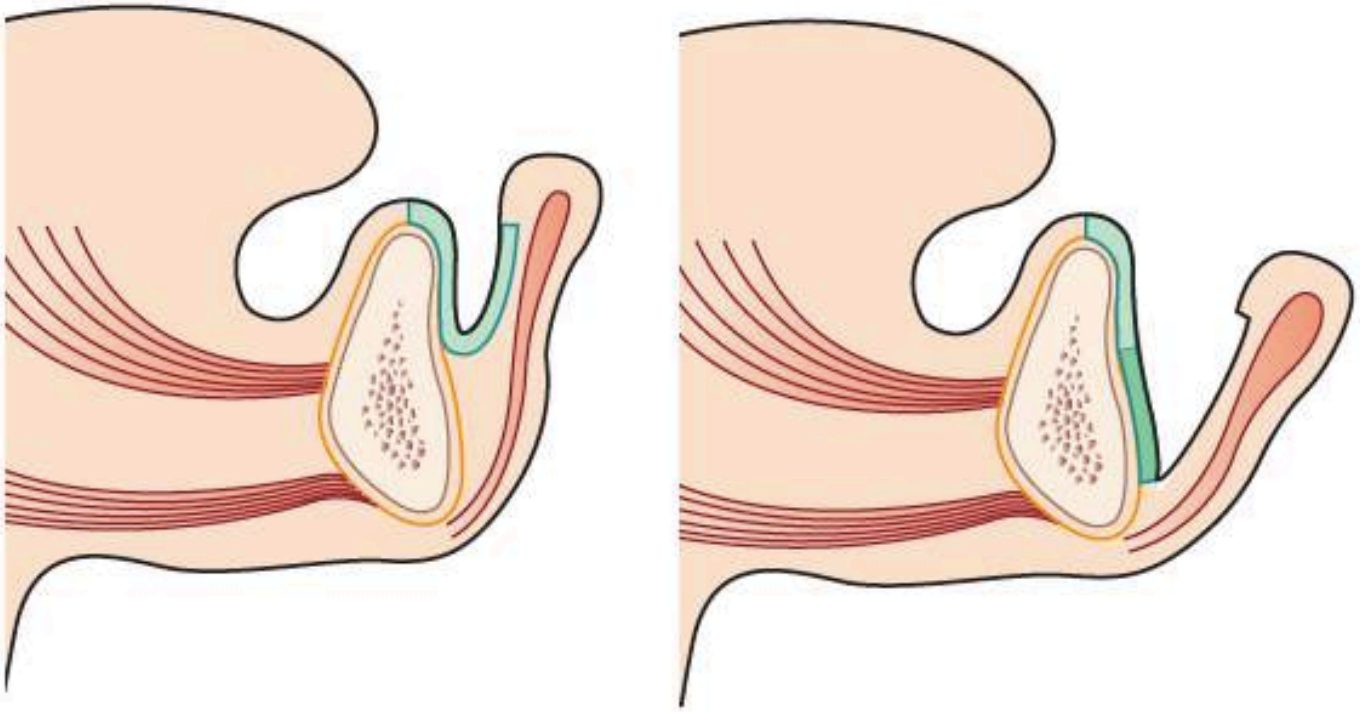

Anderson L, Kahnberg K-K, Pogrel A.
Oral and Maxillofacial Surgery. 2010.
Blackwell Publishing. Ames, Iowa.

Lip Switch Vestibuloplasty

- Modification of previous technique

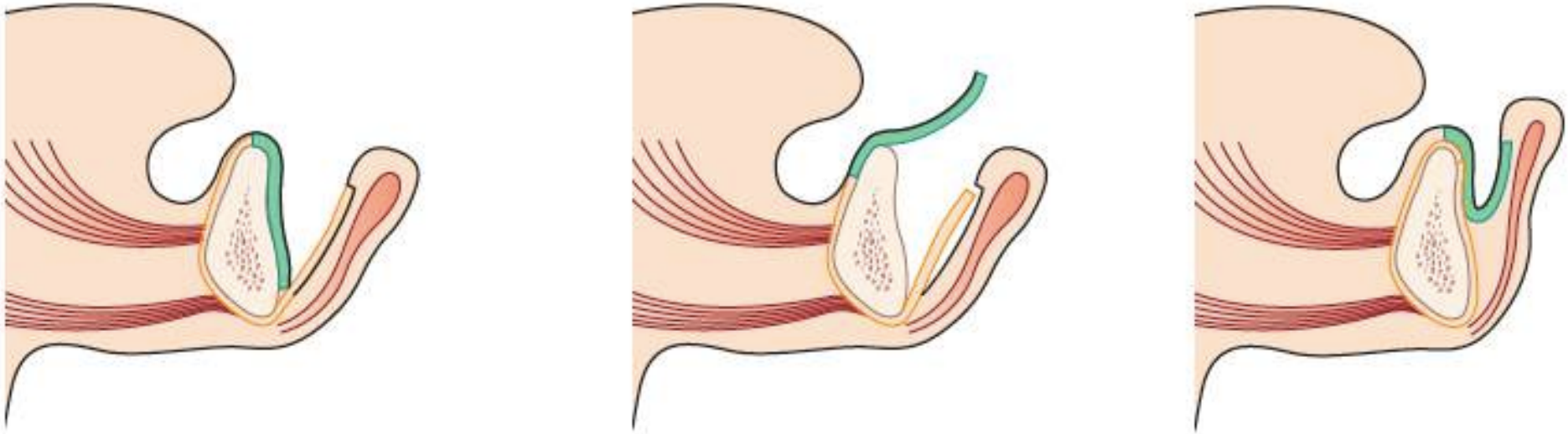

Anderson L, Kahnberg K-K, Pogrel A.
Oral and Maxillofacial Surgery. 2010.
Blackwell Publishing. Ames, Iowa.

Submucous Vestibuloplasty

- Obwegeser Submucous Vestibuloplasty
- Primarily for Maxillary use

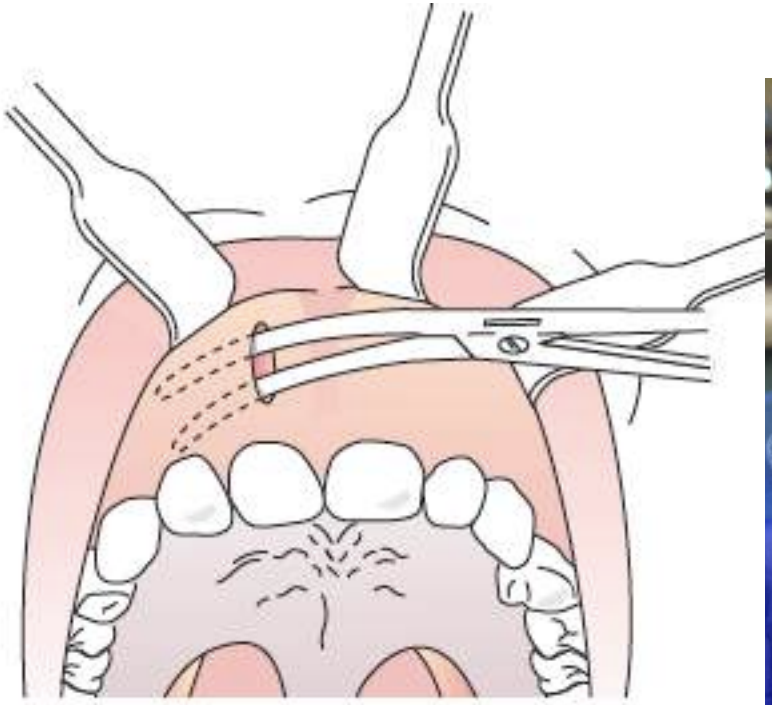

Anderson L, Kahnberg K-K, Pogrel A.
Oral and Maxillofacial Surgery. 2010.
Blackwell Publishing. Ames, Iowa.

Lowering of the Floor of Mouth

- Rare with conventional implant therapy
- Used in head and neck cancer final reconstruction in conjunction with implants
  - i.e. lowering of skin from fibula free flap with skin graft vestibuloplasty
- Submucous dissection to reposition genioglossus and mylohyoid muscle fibres
  - i.e. lowering of skin from fibula free flap with skin graft vestibuloplasty

Lowering of the Floor of Mouth

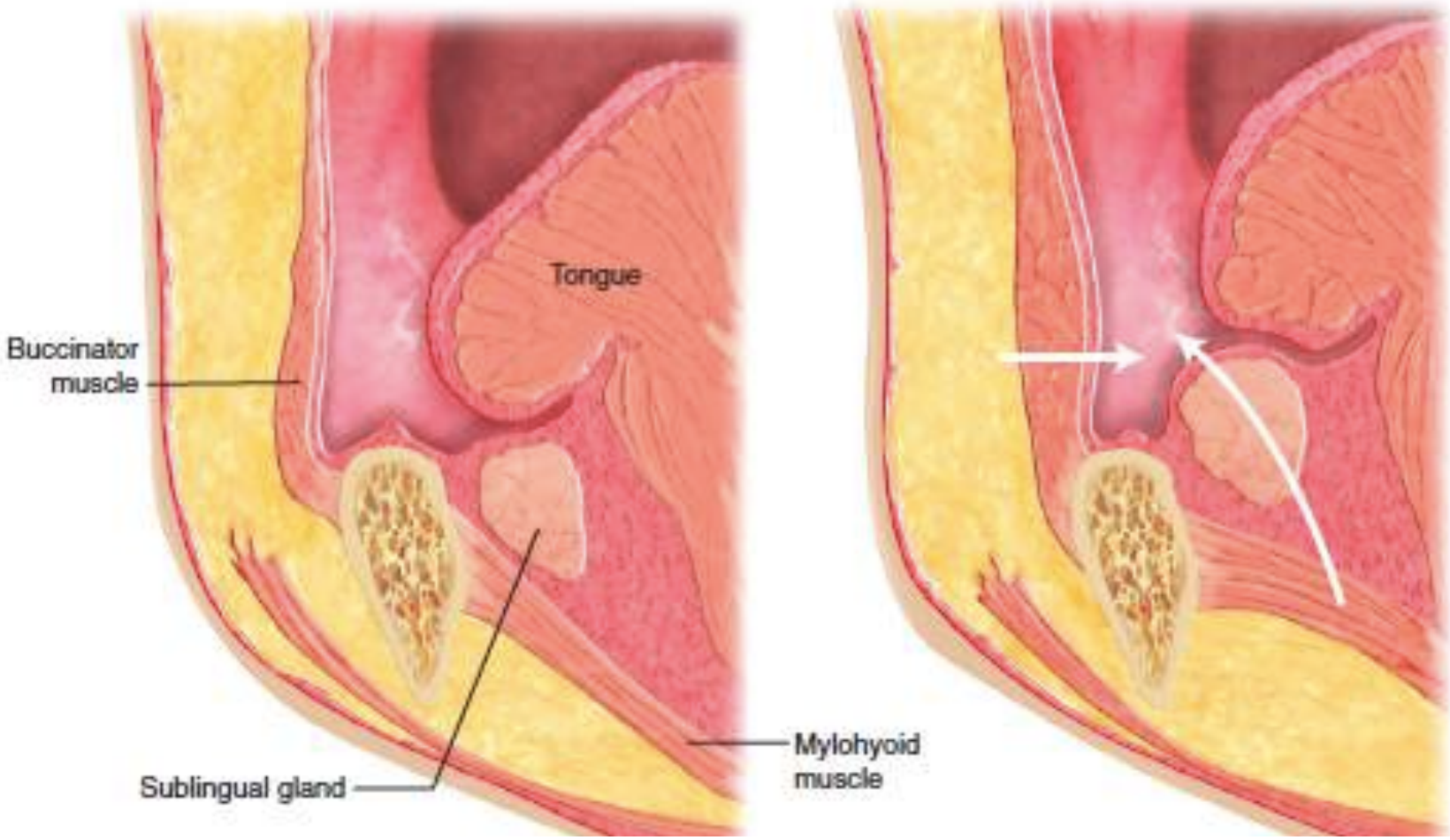

UNIVERSITY OF TORONTO
FACULTY OF DENTISTRY
ORAL AND MAXILLOFACIAL SURGERY

Lowering of the Floor of Mouth

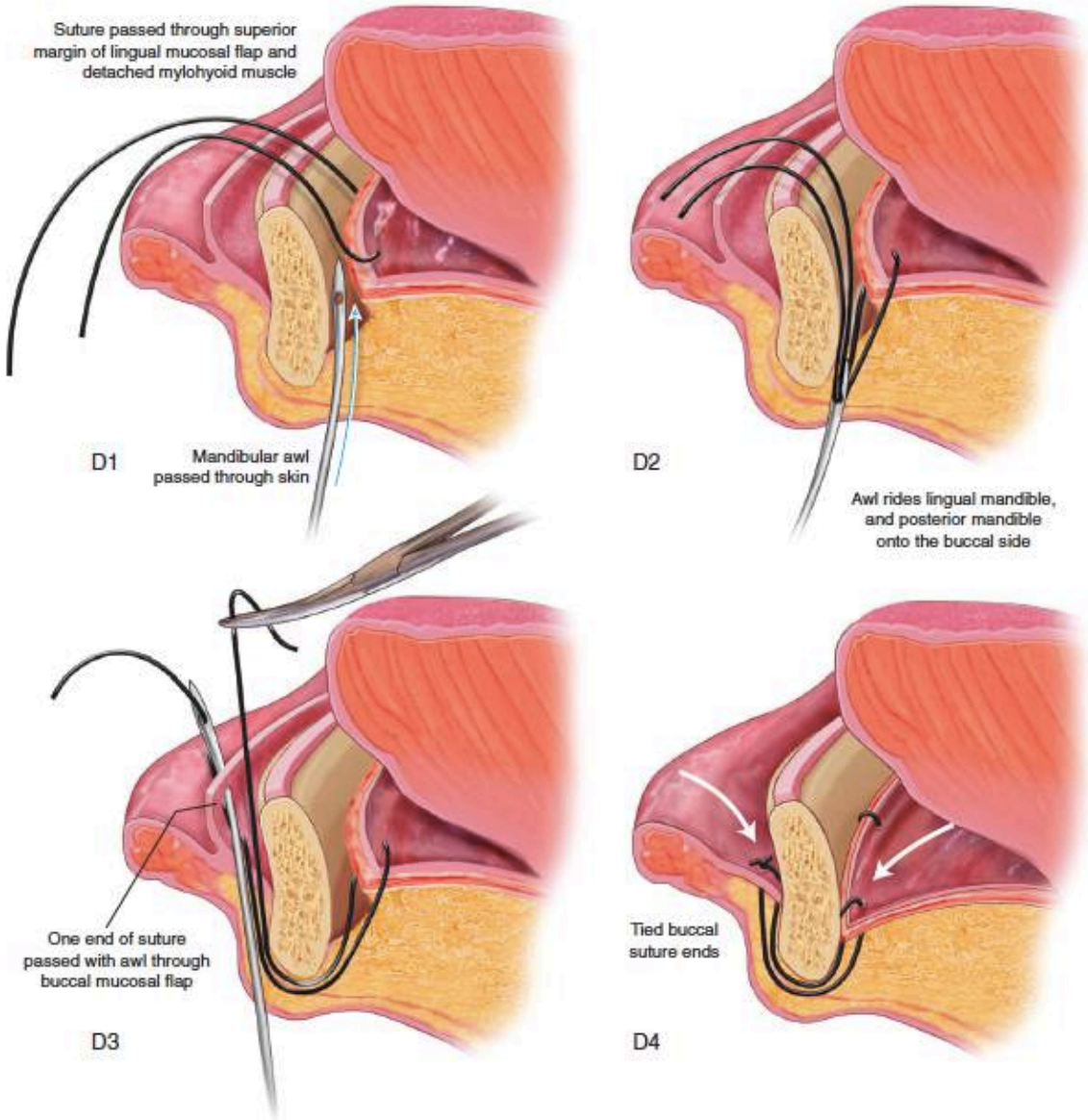

Skin Grafting

- Epidermis +/- Dermis harvested, transferred to distant site
- Requires new blood supply

- <u>Nutrient Transfer to Skin Graft at Recipient Site</u>
- First 1-2 days: Plasmatic & Serum Imbibition
- 1-4 days: Inoscultation
- 3-4 days and later: Neoangiogenesis/blood flow re-established

Split Thickness Skin Grafting

- Entire dermis not harvested
- Increased survivability
- Increased contracture
- Tolerates reduced vascularity and slightly mobile recipient bed

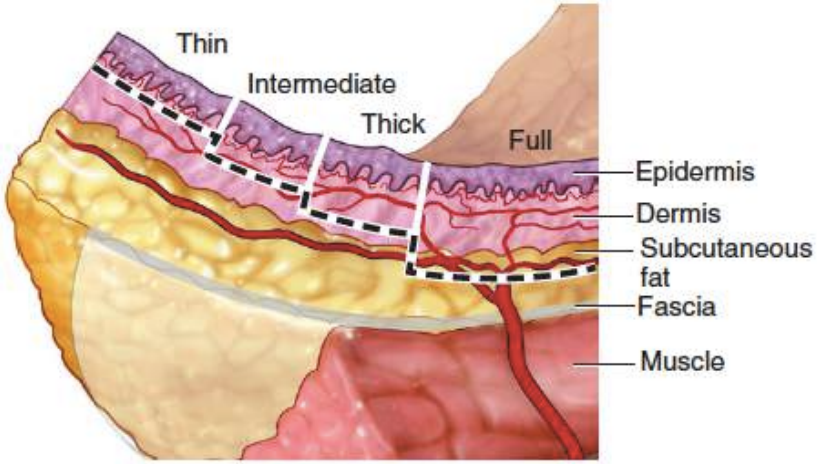

Full Thickness Skin Grafting

- Entire dermis harvested with epidermis
- Reduced survivability
- Decreased contracture
- Requires complete immobilization and good underlying recipient vasculature

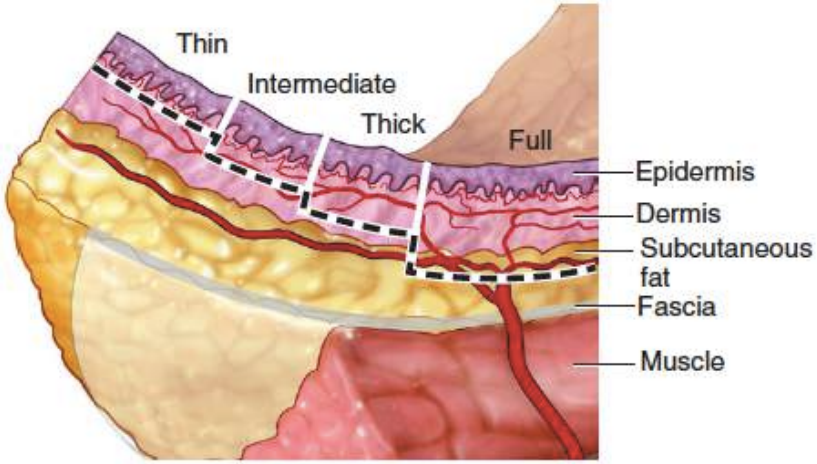

UNIVERSITY OF TORONTO
FACULTY OF DENTISTRY
ORAL AND MAXILLOFACIAL SURGERY

Correction of Skeletal Disharmonies

- Severe Skeletal Class II or III malocclusion contribute to poor denture stability and occlusion

Correction of Skeletal Disharmonies

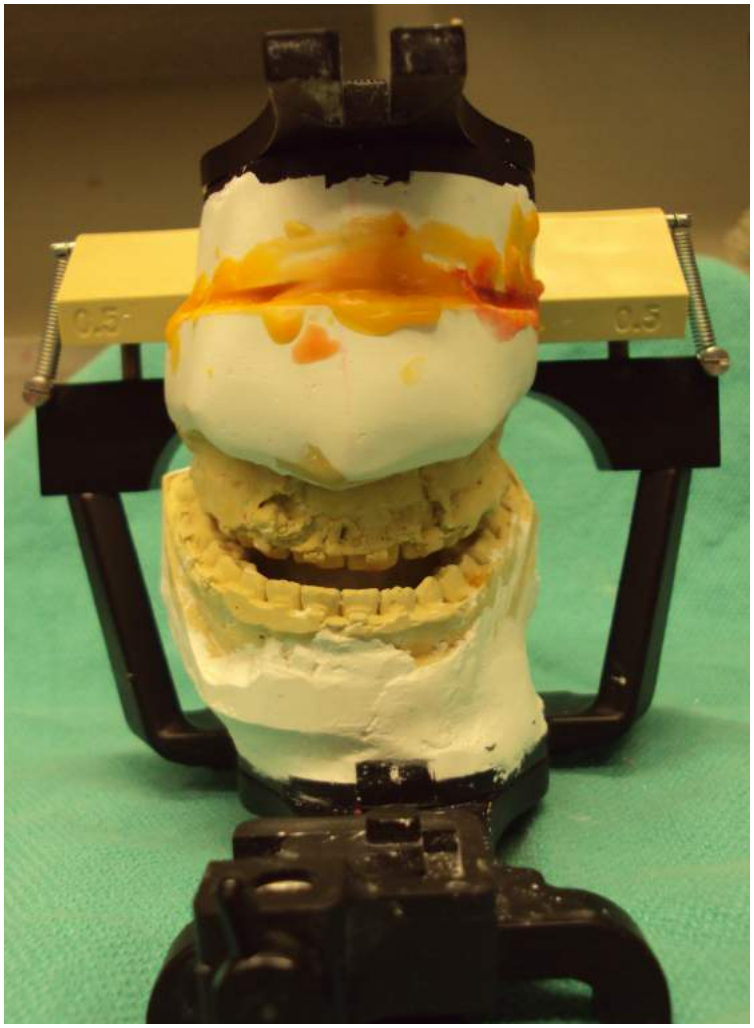

UNIVERSITY OF TORONTO
FACULTY OF DENTISTRY
ORAL AND MAXILLOFACIAL SURGERY

Correction of Skeletal Disharmonies

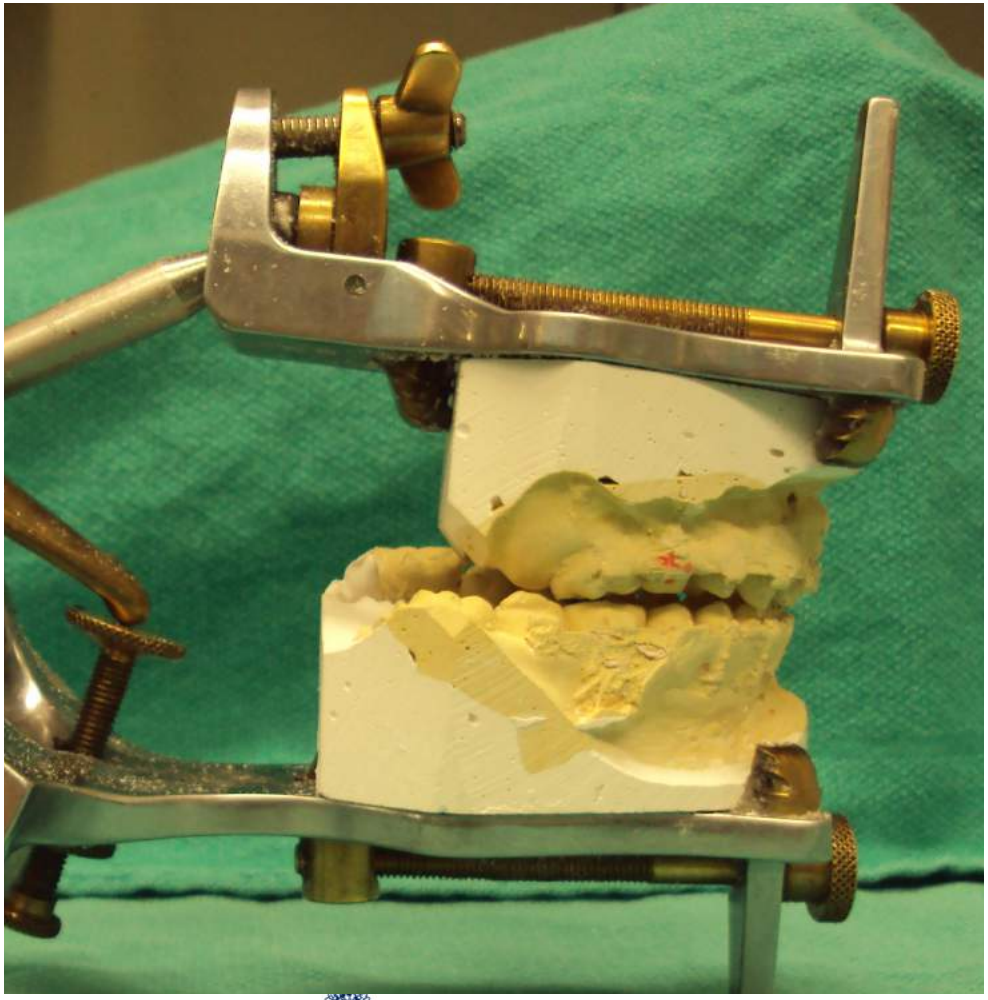

UNIVERSITY OF TORONTO
FACULTY OF DENTISTRY
ORAL AND MAXILLOFACIAL SURGERY

References

- Anderson L, Kahnberg K-K, Pogrel A. Oral and Maxillofacial Surgery. 2010. Blackwell Publishing. Ames, Iowa.
- Ephros H, Klein R, Sallustio A. Preprosthetic Surgery. Oral Maxillofacial Surg Clin N Am 27 (2015) 459-472
- Kademani D, Tiwana P. Atlas of Oral and Maxillofacial Surgery. Elsevier, 2016. St. Louis MA.
- Lawson WA. Objectives of pre-prosthetic surgery. Br J Oral Surg. 1972;10: 175-88